



# A Case of Hodgkin Transformation of Chronic Lymphocytic Leukemia

## *Kronik Lenfositik Lösemiden Hodgkin Transformasyonu Olan Bir Olgu*

Gülden Sincan, İlhami Kiki, Yusuf Bilen

Atatürk University Faculty of Medicine, Department of Hematology, Erzurum, Turkey

### Abstract

Richter's transformation is a serious complication of chronic lymphocytic leukemia. We present a patient with Hodgkin transformation of chronic lymphocytic leukemia. This patient was admitted to our clinic with the complaints of weakness and fatigue. She had palpable axillary and cervical lymphadenomegaly. Positron emission tomography/computed tomography scans with fluorodeoxyglucose revealed multiple cervical axillary lymph nodes in the right axilla and the right side of the neck with minimally increased fluorodeoxyglucose uptake and paraaortic, pancreaticoduodenal, aortocaval lymph nodes with intense fluorodeoxyglucose uptake (SUV<sub>max</sub>: 10.86). Excisional biopsy of the intraabdominal lymph node was performed which revealed classical Hodgkin disease. Combined chemotherapy was started. She died because of pneumonia after two cycles of the therapy.

**Keywords:** Chronic lymphocytic leukemia, Richter's transformation, hodgkin lymphoma

### Öz

Richter dönüşümü kronik lenfositik lösemnin ciddi bir komplikasyonudur. Biz Hodgkin lenfomaya dönüşümü olan bir kronik lenfositik lösemili olguyu sunuyoruz. Hasta kliniğimize yorgunluk ve halsizlik ile başvurdu ve palpabl sağ aksiller ve servikal lenfadenomegalileri mevcuttu. Florodeoksiglukoz pozitron emisyon tomografisi/bilgisayarlı tomografi görüntülemesi sağ aksiller ve servikal minimal; paraaortik, pankreatikoduodenal ve aortokaval belirgin artmış (SUV<sub>max</sub>: 10,86) lenf nodlarını açığa çıkardı. İntraabdominal lenf nodundan eksizyonel biyopsi yapıldı ve klasik Hodgkin lenfoma tanısı tespit edildi. Hastaya kombine kemoterapi başlandı. Bu tedaviden iki siklus sonra hasta pnömoni nedeniyle eksitus oldu.

**Anahtar Sözcükler:** Kronik lenfositik lösemi, Richter transformasyonu, hodgkin lenfoma

### Introduction

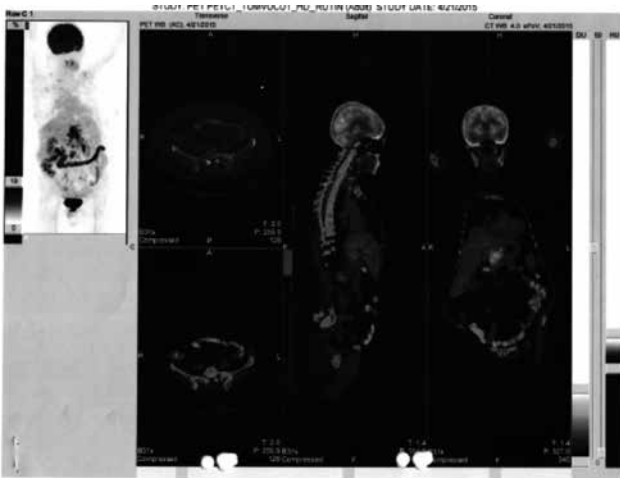
Chronic lymphocytic leukemia (CLL) is the most common type of leukemia in adults (1). The transformation of CLL to an aggressive lymphoma was first described by Richter in 1928, who reported a case of a 46-year-old man with diffuse lymphadenopathy, massive organomegaly and a rapidly fatal clinical course. The most common lymphoma seen in patients with Richter's transformation (RT) is diffuse large B-cell lymphoma. Other rare types of RT are Hodgkin variant of RT, T-cell lymphoma, lymphoblastic lymphoma, hairy cell leukaemia, and interdigitating dendritic cell sarcoma (2). The incidence of transformation to diffuse large B-cell lymphoma and Hodgkin lymphoma

(HL) is approximately 5% and 0.4%, respectively (3,4).

Sudden progression in lymphadenopathy, worsening of "B" symptoms, and elevated levels of lactate dehydrogenase (LDH) suggest RT. Positron emission tomography (PET) scan with 18F-fluorodeoxyglucose (FDG) is not recommended for diagnosis in patients with CLL; but it can be used for detection of RT of CLL. RT may occur in a single nodal or extranodal area in some cases (5). Although RT involves most frequently the lymph nodes, extranodal localizations, such as the gastrointestinal tract, skin, bone marrow, and tonsil may be seen. In this paper, we describe a 74-year-old woman with CLL who developed HL detected with PET/computed tomography (CT).

## Case

A 74-year-old female patient was admitted to our department with the complaints of fatigue and weight loss. Her past medical history included CLL for the past 11 years. She was treated with combined chemotherapy with cyclophosphamide, vincristine and prednisolone for massive and symptomatic lymphadenopathies and splenomegaly. At the end of six cycles, the lymphadenopathies recovered. On physical examination, she had palpable axillary and cervical lymphadenopathies. On evaluation of her routine laboratory tests, she was found to have a haemoglobin level of 9.9 g/dL, hematocrit 29.8%, white blood cell count 3.900/mm<sup>3</sup>, and platelet count of 170.000  $\mu$ /L. The level of serum urea was 19 mg/dL, creatinine 0.9 mg/dL, uric acid 5.4 mg/dL, LDH 348 U/L, C-reactive protein 25.4 mg/L, and  $\beta$ -2 microglobulin was 6.2 mg/L. Direct and indirect coombs tests were negative. Reticulocyte count was 1.5%. Due to anemia, elevated levels of LDH, rapidly growing lymph nodes and B symptoms, we thought that RT was the diagnosis. FDG PET/CT imaging revealed multiple lymph nodes with low FDG uptake in accordance with low-grade lymphoma involving the right axilla and the right neck. PET/CT images also revealed paraaortic, pancreaticoduodenal, aortocaval lymph nodes with intense FDG uptake (SUV<sub>max</sub> was 10.86) (Figure). Excisional biopsy of the intraabdominal lymph node which had maximum FDG uptake was performed and revealed classical Hodgkin disease. Combined chemotherapy with adriamycine, bleomycine, vinblastine, and dacarbazine (ABVD) was started. She died due to pneumonia after two cycles of ABVD therapy.



**Figure.** Positron emission tomography-computed tomography image of our case

## Discussion

CLL is the most common form of leukaemia. Hodgkin transformation is a rare condition in CLL cases. Its clinicopathological features, predictors of survival and cytogenetic abnormalities have not been well characterized to date (6). Rossi et al. (7) have reported that predisposing conditions for RT were immunoglobulin heavy chain homology, absence of del 13q14, high expression of CD38 and ZAP70, the size and number of the lymph nodes at the diagnosis, advanced Binet stage, and elevated LDH level (7). The mutations and deletions in the TP53 (p53) gene and translocations and/or amplifications in MYC are the most frequent genetic lesions in classic Richter's syndrome. In addition, it has been postulated that immunosuppressive therapy used in CLL, particularly fludarabine, might increase the risk of RT to HL. Fludarabine (and probably other purine analogues) are known to induce a marked and prolonged T-lymphocyte depletion of both CD4<sup>+</sup> and CD8<sup>+</sup> lineages, which may allow for the proliferation and accumulation of Epstein-Barr virus+ B-cells. Viral infections may also trigger RT (8).

Rapidly enlarging lymph nodes, increasing LDH level, new onset of B symptoms (fever, night sweats, and weight loss greater than 10%), and poor response to usual CLL therapies support the diagnosis of RT (6). Unfortunately, the clinical features of RT are non-specific, and suggestive laboratory findings can also frequently be seen in patients without RT. In a study by Rossi et al. (7) lymph node size  $\geq$ three cm was the clinical risk factor of RT (7). Elevated levels of LDH, B symptom and sudden enlargement of lymph nodes were present in our case. She had not taken fludarabine treatment previously. The diagnosis of Richter's syndrome requires histological confirmation. In our case, the diagnosis was confirmed by biopsy of the lymph node with high SUV<sub>max</sub>. The prognosis is poor; median survival with conventional chemotherapy is less than six months (9). In several studies, it has been reported that patients with transformed HL in the absence of active CLL seemed to have better prognosis compared with patients who had continued active CLL (A). Our case died two months after diagnosis.

Abnormal findings on PET/CT supported the clinical impression of RT in patients in whom RT was strongly suspected. In such cases, PET/CT may be of benefit by depicting the site of transformation. Site of abnormal FDG uptake with a SUV<sub>max</sub> of greater than five is considered to be highly suggestive of RT (5). Bruzzi et al. (5) have demonstrated that the overall sensitivity and specificity of PET/CT for RT was 91% and 80%, respectively, with

positive and negative predictive values of 53% and 97%, respectively (5). The  $SUV_{max}$  values of peripheral lymphadenomegalies were low in this case. Therefore, we performed excisional biopsy of the intraabdominal lymph node.

### Conclusion

Histopathological examination should be performed for the diagnosis of RT. Richter syndrome may not involve all lymph nodes simultaneously. Therefore, it is important to obtain a PET scan to guide biopsy of the suspected areas.

### Ethics

Informed Consent: Informed consent was taken from patient.

Peer-review: Externally peer-reviewed.

### Authorship Contributions

Concept: Gülден Sincan. Design: Gülден Sincan, İlhami Kiki. Data Collection or Processing: Sincan, İlhami Kiki. Analysis or Interpretation: Gülден Sincan. Literature Search: Yusuf Bilen. Writing: Gülден Sincan.

Conflict of Interest: No conflict of interest was declared by the authors.

Financial Disclosure: The authors declared that this study received no financial support.

### References

1. Motta M, Wierda WG, Ferrajoli A. Chronic lymphocytic leukemia: treatment options for patients with refractory disease. *Cancer* 2009;115:3830-41.
2. Tsimberidou AM, Keating MJ, Wierda WG. Richter's transformation in chronic lymphocytic leukemia. *Curr Hematol Malig Rep* 2007;2:265-71.
3. Tsimberidou AM, Keating MJ. Richter syndrome: biology, incidence, and the therapeutic strategies. *Cancer* 2005;103:216-28.
4. Tsimberidou AM, O'Brien S, Kantarjian HM, et al. Hodgkin transformation of chronic lymphocytic leukemia: the M.D. Anderson Cancer Center experience. *Cancer* 2006;107:1294-302.
5. Bruzzi JF, Macapinlac H, Tsimberidou AM, et al. Detection of Richter's transformation of chronic lymphocytic leukemia by PET/CT. *J Nucl Med* 2006;47:1267-73.
6. Tsimberidou AM, Wierda WG, Plunkett W, et al. Phase I-II study of oxaliplatin, fludarabine, cytarabine, and rituximab combination therapy in patients with Richter's syndrome or fludarabine-refractory chronic lymphocytic leukemia. *J Clin Oncol* 2008;26:196-203.
7. Rossi D, Cerri M, Capello D, et al. Biological and clinical risk factors of chronic lymphocytic leukaemia transformation to Richter syndrome. *Br J Haematol* 2008;142:202-21.
8. Rubin D, Hudnall SD, Aisenberg A, Jacobson JO, Harris NL. Richter's transformation of chronic lymphocytic leukemia with Hodgkin's-like cells is associated with Epstein-Barr virus infection. *Mod Pathol* 1994;7:91-8.
9. Omoti CE, Omoti AE. Richter syndrome: A review of clinical, ocular, neurological and other manifestations. *Br J Haematol* 2008;142:709-16.