



First Trimester Ultrasonographic Diagnosis of Unruptured Rudimentary Horn Pregnancies in Two Cases

Rüptüre Olmamış Rudimenter Horn Gebeliğinin İlk Trimesterdeki Ultrasonografik Tanısı: İki Olgu Sunumu

Derya Akdağ Cırık, Rıza Dur, Füsün Bocutoğlu, Nazife Kartal, Metin Kaplan, Metin Altay

Etilik Zübeyde Hanım Women's Health Training and Research Hospital, Clinic of Obstetrics and Gynecology, Ankara, Turkey

Abstract

Pregnancy in a woman with unicornuate uterus with non-communicating uterine horn is a considerably rare condition with an incidence of one in 100.000 cases. Fertilization occurs by transperitoneal migration of sperm and, uterine rupture is a considerably frequent complication of those pregnancies. Therefore, early diagnosis is of great importance due to the potential risk of maternal mortality. Herein, we present two cases of rudimentary horn pregnancy diagnosed by ultrasonography in the first trimester, and treated with laparoscopic approach. These two patients attended the hospital in the sixth and twelfth gestational weeks respectively, and the first case was misdiagnosed with tubal ectopic pregnancy in the emergency unit. After detailed transvaginal ultrasonographic examination, a gestational sac separate from the uterus and surrounded by myometrium was seen and the final diagnosis was the rudimentary horn pregnancy. The diagnosis was also confirmed after laparoscopy in both cases, and the patients underwent excision of the rudimentary horn.

Keywords: Pregnancy, rudimentary horn, unicornuate uterus, ultrasonography

Öz

Unikollis uterus ile birlikte nonkomünike rudimenter hornu olan bir kadında gebelik oluşması 100000 olguda bir görülen nadir bir durumdur. Bu gebeliklerde fertilizasyon spermin peritondan migrasyonu ile oluşur ve uterin rüptür bu gebeliklerde sık görülen bir komplikasyondur. Bu nedenle, bu gebeliklerin erken tanısı olası maternal mortalite için oldukça önemlidir. Biz de burada ilk trimesterde ultrasonografi ile erken tanısı konulan ve laparoskopi ile tedavisi yapılan iki rudimenter horn gebeliğini sunuyoruz. İki olguda hastalar sırasıyla altıncı ve on ikinci gebelik haftasında hastaneye başvurmuş olup, ilk olgu yanlışlıkla acil serviste tubal ektopik gebelik tanısı almıştır. Sonrasında yapılan detaylı ultrasonografik incelemede, uterusun ayrı olarak gestasyonel kese ve çevresinde miyometriyum izlenmiş ve hastalarda rudimenter horn gebeliği tanısı kesinleşmiştir. Laparoskopiyeye alınan iki olguya da tedavi amacıyla rudimenter horn eksizyonu yapılmıştır.

Anahtar Sözcükler: Gebelik, rudimenter horn, unikollis uterus, ultrasonografi

Introduction

Unicornuate uterus with a rudimentary horn is one of the lateral fusion defects. This uterine anomaly occurs with the hypoplasia of the contralateral Mullerian duct and development of unilateral Mullerian duct. Pregnancy in the non-communicating horn, which exists by transperitoneal

migration of sperm, is seen in one of 100.000 pregnancies (1). Rudimentary horn pregnancies are also important for maternal mortality, since more than 80% of cases are diagnosed after uterine rupture (2). We therefore, aimed to present two cases of non-communicating rudimentary horn pregnancies diagnosed by ultrasonographic investigation in the first trimesters in our clinic.

Address for Correspondence/Yazışma Adresi: Derya Akdağ Cırık
Etilik Zübeyde Hanım Women's Health Training and Research Hospital, Clinic of Obstetrics and Gynecology, Ankara, Turkey Phone: +90 312 567 40 00/4330 E-mail: deryaakdag@yahoo.com

Received/Geliş Tarihi: 01 February 2016 **Accepted/Kabul Tarihi:** 07 February 2016

*The Medical Bulletin of Haseki Training and Research Hospital,
published by Galenos Publishing.*

*Haseki Tıp Bülteni,
Galenos Yayınevi tarafından basılmıştır.*

Case Reports

Case 1

A 38-year-old patient (five gravidities, three parities, one abortion and three living children), who was in the sixth week of pregnancy according to her last menstrual period, was admitted to our emergency room with the only complaint of delayed menses and abdominal discomfort. Physical and abdominal examinations of the patient did not indicate any abnormal sign. Her gynecological examination revealed a mobile uterus in normal size, and a mobile mass about 5 cm in size in the right adnexal area with regular margins. The β -hCG value was determined to be 8625 mIU/mL, and she was hospitalized with the initial diagnosis of tubal ectopic pregnancy. Her transvaginal ultrasonographic examination performed in the early pregnancy ultrasonography unit after her hospitalization did not reveal a gestational sac in the cavity. The endometrial thickness was found to be 20 mm; in addition, a rudimentary horn pregnancy, which was 17x19 mm in size was visualized in a separate cavity, left lateral of the empty uterus. This gestational sac was surrounded by a regular hyperechogenic halo, and was considered to include a myometrium (Figure 1a). The patient was informed about her situation, and she underwent laparoscopy. Intraoperative laparoscopic investigation revealed a rudimentary horn, which was about 4-5 cm in diameter and was connected to the uterus with a fibrous band on the right side (Figure 1b). Right ovary and tuba connected with the rudimentary horn and left ovary and tuba connected with the unicornuate uterus in the left were also visualized. The rudimentary horn and tuba were excised, but the right ovary was preserved.

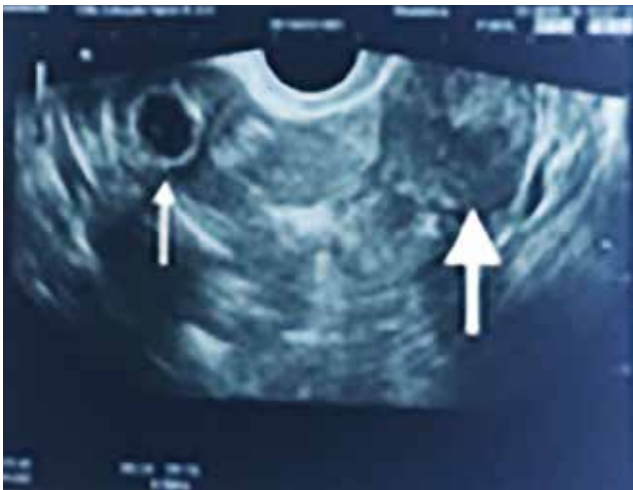

Figure 1a. A transvaginal ultrasonography of sixth weeks of pregnancy in a rudimentary horn: Thin arrow shows the gestational sac in the rudimentary horn, separate from the main uterus and the thick arrow shows the normal unicornuate uterus on the right side

The rudimentary horn and the pregnancy material were taken out of the abdomen with endobag (Figure 1c). Histopathological investigation revealed decidua and chorionic villi in the rudimentary horn, and, thus, the final diagnosis was made.

Case 2

A 31-year-old, 12 weeks' pregnant patient according to her last menstrual period (three gravidities, two parities, and two living children) attended our hospital for the first trimester screening test. The level of β -hCG was found to be 105544 mIU/mL. In the ultrasonographic examination, it was observed that the pregnancy was not within the main uterine cavity and was located in another separate uterine cavity. Pelvic examination revealed a single external cervical orifice, and unicornuate uterus was softly palpable in the anterior. In the detailed ultrasonographic evaluation, a rudimentary horn was visualized on the left side of the unicornuate uterus; the rudimentary horn included a twelfth weeks pregnancy with 59 mm CRL. A corpus luteum was observed in the left ovary which existed on the same side of the rudimentary horn. The right ovary and tuba appeared normal. After informed consent, a laparoscopy was planned for the following day. Intraoperative laparoscopy revealed a unicornuate uterus on the right that was in continuation with the cervix, and in normal appearance (Figure 2a). On the left side, a thinned non-communicating rudimentary horn was visualized including a 12 weeks pregnancy material, and it existed with a tendency to rupture. Endometrial biopsy was applied to the right uterine cavity. On the left side, salpingectomy and excision of the left rudimentary horn were performed. The material was extracted with endobag by enlarging the umbilical incision. Histopathological evaluation revealed a rudimentary horn with decidua and chorionic villi, a 3.5-month old male fetus, and uterine muscle tissue (Figure 2b).

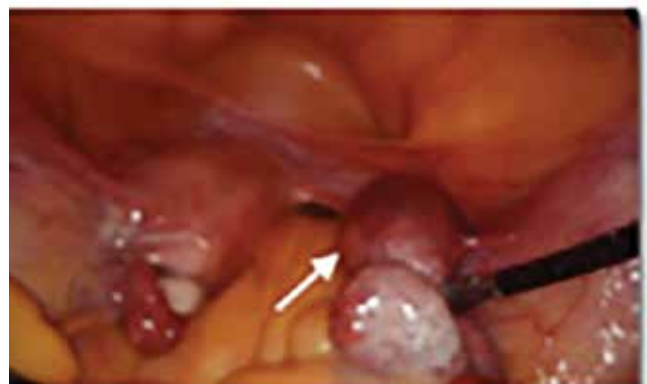

Figure 1b. Intraoperative photograph of the case: The arrow shows the non-communicating rudimentary horn that is separate from the unicornuate uterus. There is a fibrous band between these structures

Discussion

Unicornuate uteri have been classified in four groups by the American Society for Reproductive Medicine as follows; a rudimentary horn communicating with the uterus, non-communicating with the uterus and including endometrial cavity, non-communicating with the uterus and not including endometrial cavity, and isolated unicornuate (3). Rudimentary horn pregnancies are rarely reported in the literature. Myometrium in the rudimentary horn is thin, and the endometrium may be nonfunctional; therefore, severe complications like placenta accreta and uterine rupture are considerably frequent in these pregnancies (4). Rudimentary horn pregnancies have serious risks regarding the maternal and perinatal mortalities; early diagnosis therefore has vital importance for the mother. Although the non-communicating rudimentary horn could be diagnosed before pregnancy with hysterosalpingography and laparoscopy, and transvaginal ultrasonography is preferred when pregnancy exists; only 22% of cases can be diagnosed accurately with ultrasonography. Magnetic resonance imaging, which is especially performed in the late gestational weeks, possesses a high diagnostic success, however, it is considerably expensive for the routine application. In our study, prenatal diagnosis could be achieved by transvaginal ultrasonography in both cases, in their first trimesters.

Three states that can be confused with this diagnosis in ultrasonographic examination are as follows; tubal ectopic pregnancy, cornual pregnancy and an intrauterine pregnancy in a bicornuate uterus. As it was also the fact in our cases, the initial diagnosis of the patients is generally tubal ectopic pregnancy. However, differential diagnosis

can easily be made with the absence of myometrium surrounding the gestational sac in the tubal ectopic pregnancy. A large distance between the two uterine cornua, and difference in the thickness of myometrium are the signs for considering a rudimentary horn pregnancy. In bicornuate uterus, endometrium within the gestational sac is in continuation with the other uterine horn. Diagnostic criteria for rudimentary horn pregnancies suggested by Tsafrir et al., (5) are as follows; similar appearance to an asymmetric bicornuate uterus, disconnection between the horn with pregnancy and the endocervical canal and the existence of myometrial tissue around the gestational sac. In addition, existence of hypervascularization similar to placenta accreta also supports the diagnosis.

Rupture risk increases in the rudimentary horn pregnancies that have reached up to the thirteenth gestational week, as also existed in our second case. This case was diagnosed during her attendance for the first trimester screening test, because of the suspected appearance in the ultrasonographic examination. In a study by O'leary and O'leary (6) that investigated 328 pregnancies existing in the non-communicating rudimentary horn, it was reported that only 1% of these

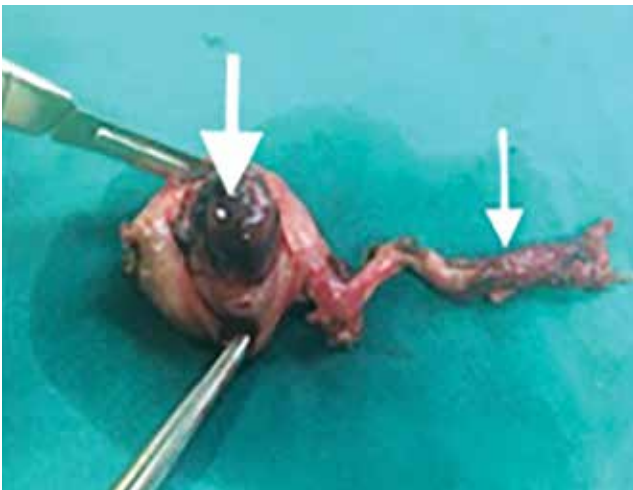


Figure 1c. Morphological examination of the rudimentary horn pregnancy after excision of the horn. The thick arrow shows the gestational tissue in the rudimentary horn and the thin arrow shows the fibrous band between rudimentary horn and unicornuate uterus

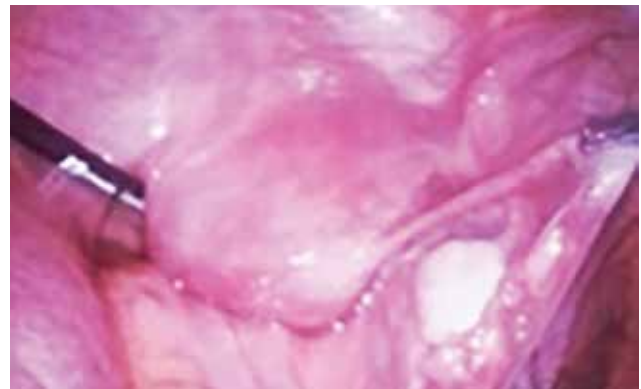

Figure 2a. Intraoperative photograph shows the rudimentary horn separated from the unicorn uterus. On the left side unicorn uterus is shown

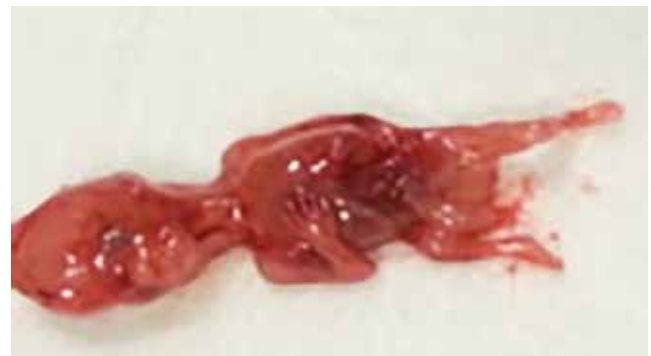

Figure 2b. Morphologic examination of twelfth weeks of gestation extracted from the rudimentary horn

pregnancies reach term viable, and that 89% of them result in rupture. There are studies reporting that conservative approach may be preferred till the maintenance of viability in the selected cases that exist with a thick myometrial layer around the gestational sac. However, since these pregnancies may result in rupture both spontaneously and when induced, current studies recommend surgical excision and termination in these pregnancies as soon as they have been diagnosed (7). In the cases diagnosed early in their first trimesters, as cases presented in our study, laparoscopic surgery is accepted to be the standard surgical treatment. However, pregnancy in the rudimentary horn enlarges in the advanced gestational weeks and, thus, laparotomy exists as the treatment of choice.

Conclusion

As a conclusion, rudimentary horn pregnancy is a considerably rare condition. In the cases diagnosed with sonographic guidance in the first trimester, it can safely be treated by laparoscopic approach. However, when it is missed out for any reason, it can lead to maternal morbidity and mortality because of the rupture resulting in severe intraabdominal bleeding. Therefore, specific sonographic signs of the rudimentary horn pregnancy have to be known by all physicians who follow-up the pregnant cases. Surgical treatment is essential in such pregnancies, and when suspected, the cases have to be referred without delay to a tertiary medical center for diagnostic confirmation and treatment.

Ethics

Informed Consent: It was taken.

Peer-review: Internal peer-reviewed.

Authorship Contributions

Concept: Derya Akdağ Cırık, Metin Altay. Design: Rıza Dur, Metin Kaplan. Data Collection or Processing: Füsün Bocutoğlu, Nazife Kartal. Analysis or Interpretation: Derya Akdağ Cırık, Rıza Dur. Literature Search: Metin Kaplan, Füsün Bocutoğlu, Nazife Kartal. Writing: Derya Akdağ Cırık, Rıza Dur.

Conflict of Interest: No conflict of interest was declared by the authors.

Financial Disclosure: The authors declared that this study received no financial support.

References

1. Panayotidis C, Abdel-Fattah M, Leggott M. Rupture of rudimentary uterine horn of a unicornuate uterus at 15 weeks' gestation. *J Obstet Gynaecol* 2004;24:323-4.
2. Edelman AB, Jensen JT, Lee DM, et al. Successful medical abortion of a pregnancy within a noncommunicating rudimentary uterine horn. *Am J Obstet Gynecol* 2003;189:886-7.
3. The American Fertility Society classifications of adnexal adhesions, distal tubal occlusion, tubal occlusion secondary to tubal ligation, tubal pregnancies, mullerian anomalies and intrauterine adhesions. *Fertil Steril* 1988;49:944-55.
4. Nahum GG. Rudimentary uterine horn pregnancy. The 20th-century worldwide experience of 588 cases. *J Reprod Med* 2002;47:151-63.
5. Tsafirir A, Rojansky N, Sela HY, et al. Rudimentary horn pregnancy: first-trimester prerupture sonographic diagnosis and confirmation by magnetic resonance imaging. *J Ultrasound Med* 2005;24:219-23.
6. O'Leary JL, O'Leary JA. Rudimentary Horn Pregnancy. *Obstet Gynecol* 1963;22:371-5.
7. Reichman D, Laufer MR, Robinson BK. Pregnancy outcomes in unicornuate uteri: a review. *Fertil Steril* 2009;91:1886-94.