



# The Effect of Platelet-Rich Fibrin on Postoperative Morbidity after Rhinoplasty: A Comparative Analysis with Respect to Edema, Ecchymosis and Pain

Enes Yigit, Tolga Kirgezen, Ozan Ozdemir, Muhammet Ture, Abdurrahman Cagliyan, Ozgur Yigit

University of Health Sciences Turkey, Istanbul Training and Research Hospital, Clinic of Otorhinolaryngology, Istanbul, Turkey

## Abstract

**Aim:** Platelet-rich fibrin (PRF) effectively improves the surgical effect in augmentation rhinoplasty; while there are a limited number of studies regarding its impact on postoperative morbidity in primary open rhinoplasty with conventional osteotomy (COS). This study was designed to investigate the utility of PRF in reducing the short-term postoperative morbidity in primary open rhinoplasty with conventional osteotomy.

**Methods:** A total of 61 adult patients who underwent primary open rhinoplasty with conventional osteotomy, either alone (COS group; n=31) or combined with the application of PRF over the osteotomy line (COS-PRF group; n=30) were included in this prospective study conducted between March 1, 2020 and March 1, 2021. Data on postoperative morbidity, including edema and periorbital ecchymosis (on postoperative day 2 and day 7), pain [via visual analogue scale (VAS) and verbal rating scale (VRS)] and the analgesic use (on postoperative days 1, 2, 3 and 7) were recorded.

**Results:** COS and COS-PRF groups were similar in terms of the likelihood of eyelid edema and periorbital ecchymosis on any postoperative day. The study groups were also similar in terms of average VAS (median 2.5 vs. 2.4, p=0.680) and VRS (median 1.5 vs. 1.4, p=0.521) scores and the number of analgesics used (median 1.5 vs. 1.3, p=0.196) during the 7-day postoperative period and daily VAS, VRS and analgesic usage records.

**Conclusion:** Our findings indicate no significant impact of using local PRF application over osteotomy line in reducing postoperative eyelid edema, periorbital ecchymosis, or pain within the first postoperative week of open rhinoplasty.

**Keywords:** Platelet-rich fibrin, rhinoplasty, osteotomy, morbidity

## Introduction

Rhinoplasty is one of the most commonly performed and most challenging procedures in facial plastic surgery due to complex interplay among the different tissues and anatomical regions of the nose (1-3).

Postoperative pain, edema and ecchymosis, albeit minor and temporary in general, are the main postoperative morbidities following rhinoplasty, and their duration and severity change depending on the degree of soft-tissue injury and types of osteotomies and surgical techniques (1,2). Given the strategic position of the nose on the face and its aesthetic and functional importance,

reducing the amount and duration of ecchymosis, edema and pain after rhinoplasty is considered important due to the likelihood of a significant practical, emotional, and financial (lost work days) effect on patients even they are minor consequences (1,3).

In this regard, various techniques, instruments, and intra- and postoperative methods and biomaterials (i.e., intraoperative steroid injection, intraoperative cold, saline-soaked gauze compression, postoperative taping, piezoelectric surgery, creation of subperiosteal tunnels) have been employed by surgeons in terms of their efficacy in reducing these uncomfortable morbidities, and thus

**Address for Correspondence:** Enes Yigit,  
University of Health Sciences Turkey, Istanbul Training and Research Hospital, Clinic of  
Otorhinolaryngology, Istanbul, Turkey  
Phone: +90 212 459 62 30 E-mail: enesyigit@hotmail.com ORCID: orcid.org/0000-0002-9853-6238

**Received:** 02.01.2022 **Accepted:** 13.04.2022

©Copyright 2022 by The Medical Bulletin of  
Istanbul Haseki Training and Research Hospital  
The Medical Bulletin of Haseki published by Galenos Yayinevi.

to enable optimal healing, scar tissue formation and the intended morphologic result (2-5).

Platelet-rich fibrin (PRF), a second-generation platelet concentration that activates wound healing through increased fibroblast and growth factor, has been mainly used in orthopedic and dental procedures (6,7). As an autologous biomaterial rich in leukocytes and platelets, PRF is considered to generate a smaller inflammatory response and rejection than other types of biomaterials (1,8).

PRF has also become increasingly popular in facial plastic and reconstructive surgery, due to its proposed efficacy in decreasing edema and ecchymosis, improved hemostasis, and expedited postoperative recovery (9,10).

Although, the role of PRF alone or in mixed with cartilage tissue or high-density fat effectively improves the surgical effect in augmentation rhinoplasty (11-14), there are a limited number of studies regarding the impact of PRF on postoperative morbidity in primary open rhinoplasty with conventional osteotomy.

This study investigated the utility of PRF in reducing the short-term postoperative morbidity (edema, ecchymosis and pain) in primary open rhinoplasty with conventional osteotomy

## Materials and Methods

### Study Design and Ethical Considerations

A total of 61 consecutive adult patients who underwent primary open rhinoplasty with conventional osteotomy were included in this prospective study conducted between March 1, 2020 and March 1, 2021. Patients were randomly assigned to two groups including conventional osteotomy alone [COS group; n=31, mean  $\pm$  standard deviation (SD) age: 24.8 $\pm$ 8.0 years, 83.9% were females] and conventional osteotomy plus application of PRF over the osteotomy line (COS-PRF group; n=30, mean  $\pm$  SD age: 23.9 $\pm$ 5.4 years, 83.3% were females). The presence of a previous history of rhinoplasty, ongoing anticoagulant treatment, hypertension, chronic disease, bleeding diathesis, inflammatory skin disease and skin allergy were the exclusion criteria of the study. Written informed consent was obtained from each patient following a detailed explanation of the objectives and protocol. The study was conducted in accordance with the ethical principles stated in the "Declaration of Helsinki" and ethical approval for this study was obtained from the University of Health Sciences Turkey, Istanbul Training and Research Hospital Clinical Research Ethics Committee (approval no: 2011-KAEK-50/2687, date: 22.01.2021).

### Assessments

Data on patient demographics (age, gender), nasal skin thickness (thin: <1 cm, normal: 1-2 cm and thick: >2 cm), operative time minute (min) and postoperative morbidity, including edema (right and left, on postoperative day 2 and day 7), periorbital ecchymosis (right and left, on postoperative day 2 and day 7), pain (on postoperative days 1, 2, 3 and 7) via visual analogue scale (VAS) and verbal rating scale (VRS), and the analgesic use (number of daily tablets on postoperative days 1, 2, 3 and 7) were recorded in COS and COS-PRF groups.

### PRF Protocol

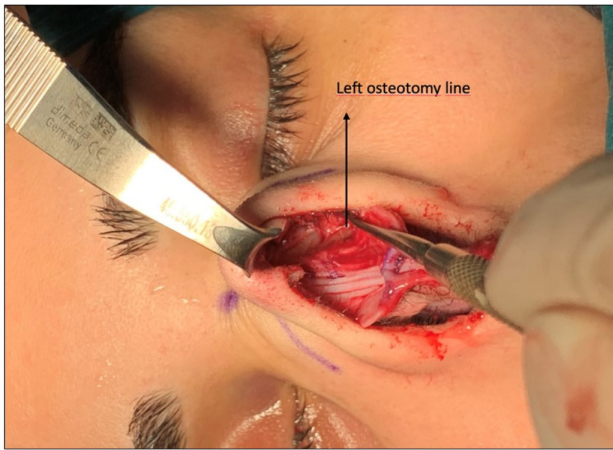
In the COS-PRF group, as per the PRF protocol that requires single centrifugation without the addition of an anticoagulant; 10 mL of venous blood was taken approximately 15 min before the completion of operation and added to sterile glass tubes and immediately centrifuged at 3000 rpm for 10 min. The fibrin clot formed in the middle layer, in which most of the platelets and leucocytes are concentrated, was used as PRF, while the topmost layer that consists of cellular plasma was removed. PRF was applied to the osteotomy line during open rhinoplasty in the COS-PRF group.

### Rhinoplasty Procedure

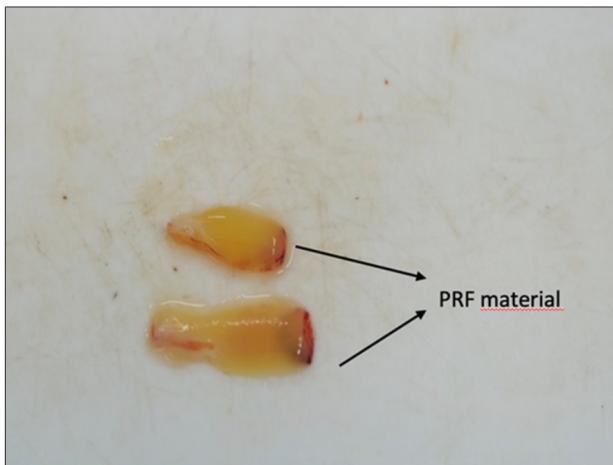
The same senior surgeon performed all the operations through an open approach. Following a mid-columellar v incision, the nasal skeleton was exposed in the subperichondrial and subperiosteal surgical anatomical plane. The complete subperiosteal degloving of the entire nasal bone up to the nasal maxillary sulcus, medial canthus, and nasion was performed with cauterization of visible vessels to minimize the soft-tissue injury. Afterwards, septal mucoperichondrium was elevated bilaterally and cartilage grafts were harvested from cartilaginous septum to be used in nasal reshaping and reconstruction. The nasal dorsal hump was removed via Rubin Osteotome, while median-oblique and lateral osteotomy, using a conventional 2 mm guarded straight osteotome, was performed following nasal tip plasty. Cold ice-soaked gauze compression was applied to control small vessel bleeding following the osteotomies and to prevent edema and ecchymosis. In the COS-PRF group, PRF material was applied to the osteotomy line bilaterally just before the skin closure. In all patients, nasal tamponing was performed for 24 h and an external nasal splint was applied for 7 days (Figure 1 and 2).

### Postoperative Edema and Ecchymosis

Postoperative eyelid edema and periorbital ecchymosis were assessed on postoperative days 2 and 7 by the two independent surgeons not participated in surgery and blinded to the study protocol.



**Figure 1.** Rhinoplasty procedure: exposed nasal bone (Informed consent was obtained)



**Figure 2.** Prepared PRF material  
PRF: Platelet-rich fibrin

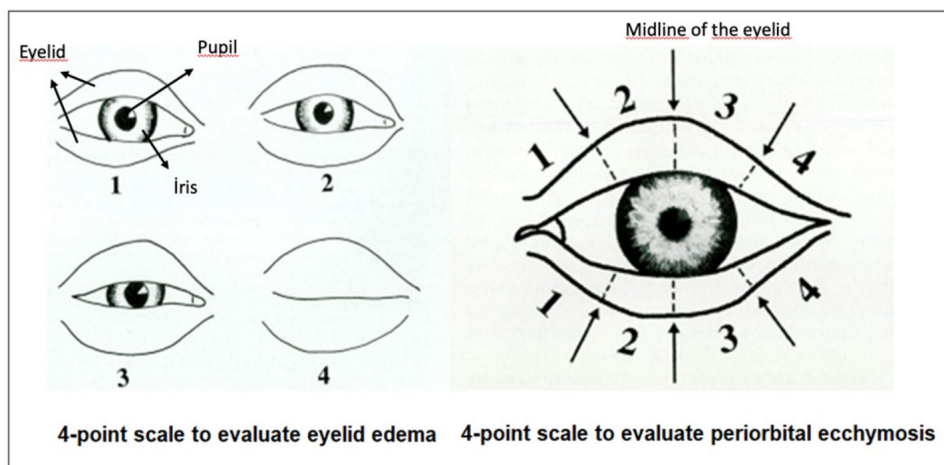
The eyelid edema and periorbital ecchymosis were scored from 0 to 4, according to a graduated scoring system (15). Accordingly, eyelid edema was scored using a 4-point scale (0: no edema, 1: minimal edema, 2: edema extending onto iris without closing the eyelids, 3: edema covering the iris and extending to the pupil but not to eyelids and 4: massive edema with the eyelid swollen shut) (Figure 3).

Periorbital ecchymosis was scored using a 4-point scale (0: no ecchymosis, 1: ecchymosis involving 1/4 of the medial part of the eyelid, 2: ecchymosis involving 1/2 of the medial part of the eyelid extending to pupil, 3: ecchymosis passing the midline of the eyelid involving the maximum 3/4 of eyelid, 4: exceeds 3/4 of the eyelid and covers the eyelid completely) (Figure 3).

### Visual Analogue Scale

The pain VAS is a self-administered unidimensional psychometric response scale used to measure pain intensity, which has been widely used in diverse adult populations. It is a continuous 10 cm scale anchored by 2 verbal descriptors for pain intensity, including “no pain” (score of 0) and “worst imaginable pain” (score of 10). Participants were asked to make a mark on the line that represented their pain intensity, and the pain intensity level was scored by measuring the distance from the “no pain” end to the patient’s mark. VAS provides a range of scores from 0-10 with higher scores indicating greater pain intensity (16).

VRS is a continuous scale anchored by verbal descriptors for pain intensity, including no pain, mild pain, disturbing pain, severe pain, extreme pain and worst imaginable pain. The scores 0, 2, 4, 6, 8, and 10 were assigned to each verbal descriptor, with “none” scored as 0 to “worst pain” scored 10, with higher numbers associated with more intense adjectives. Participants are asked to pick the



**Figure 3.** Scoring system used for assessment of postoperative eyelid edema and periorbital ecchymosis

word that best described their pain intensity, and their VDS intensity score is the number associated with the word they chose (16).

### Statistical Analysis

Statistical analysis was performed using MedCalc® Statistical Software version 19.7.2 (MedCalc Software Ltd, Ostend, Belgium; <https://www.medcalc.org>; 2021). Shapiro-Wilks test was used to investigate the normal distribution. Descriptive statistics were reported for categorical data. Chi-square test (Yates continuity correction or Fisher's exact test where available) was used for the analysis of categorical variables. Mann-Whitney U test was used to compare two independent non-normally distributed variables. Data were expressed as "mean ± SD, median (minimum-maximum) and percentage (%)" where appropriate.  $P < 0.05$  was considered statistically significant.

## Results

### Baseline Characteristics

No significant difference was noted between the COS and COS-PRF groups in terms of patient age (mean ± SD 24.8±8.0 vs. 23.9±5.4 years), gender (females: 83.9 vs. 83.3%), nasal skin thickness (normal: 58.1 vs. 63.3%) or operative time (mean ± SD 218.5±35.4 vs. 210±23.8 min) (Table 1).

### Postoperative Eyelid Edema and Periorbital Ecchymosis

On postoperative day 2, grade 3 eyelid edema was more prevalent in both the COS (58.1% on the right side and 61.3% on the left side) and COS-PRF (53.3% on the right side and 40.0% on the left side) groups. On postoperative day 7, grade 1 edema was more prevalent in both the COS (74.2% on both sides) and COS-PRF (60.0% on the right side and 66.7% on the left side) groups (Table 2, Figure 4).

On postoperative day 2, grade 2 to 3 periorbital ecchymosis was more prevalent in both the COS (70.0% on the right side and 64.6% on the left side) and COS-PRF (46.6% on the right side and 60.0% on the left side) groups. On postoperative day 7, periorbital ecchymosis was not evident or was at grade 1 in most patients in both the COS (100.0% on the right side and 93.5% on the left side) and COS-PRF (93.4% on the right side and 90.0% on the left side) groups (Table 2, Figure 4).

No significant difference was noted between the COS and COS-PRF groups in terms of the likelihood of eyelid edema and periorbital ecchymosis on any postoperative day (Table 2).

### Postoperative Pain and Analgesic Use

No significant difference was noted between the COS and COS-PRF groups in terms of average VAS scores during the 7-day postoperative period (median 2.5 vs. 2.4,  $p=0.680$ ) as well as daily VAS records on day 1 (median 3.0 for each), day 2 (median 4.0 for each), day 3 (median 3.0 and 2.0 respectively) and day 7 (median 0 for each) (Table 3, Figure 5).

No significant difference was noted between the COS and COS-PRF groups in terms of average VRS scores during the 7-day postoperative period (median 1.5 vs. 1.4,  $p=0.521$ ) as well as daily VRS records on day 1 (median 1.0 vs. 2.0, respectively), day 2 (median 2.0 for each), day 3 (median 2.0 and 1.0 respectively) and day 7 (median 0 for each) (Table 3, Figure 5).

No significant difference was noted between the COS and COS-PRF groups in terms of the average number of analgesics used during the 7-day postoperative period (median 1.5 vs. 1.3,  $p=0.196$ ) as well as the daily number of medications on day 1 (median 1.0 for each), day 2 (median 3.0 vs. 2.0, respectively), day 3 (median 2.0 and 1.0 respectively) and day 7 (median 0 for each) (Table 3, Figure 5).

**Table 1. Baseline characteristics in the COS vs. COS-PRF groups**

		COS (n=31)	COS-PRF (n=30)	p-value
Age (year)	Mean ± SD	24.8±8.0	23.9±5.4	0.965 <sup>1</sup>
	Median (min.-max.)	22 (17-52)	22 (19-39)	
Gender, n (%)				
Female		26 (83.9)	25 (83.3)	>0.05 <sup>2</sup>
Male		5 (16.1)	5 (16.7)	
Operative time (min.)	Mean ± SD	218.5±35.4	210±23.8	0.279 <sup>3</sup>
	Median (min.-max.)	225 (155-285)	210 (175-255)	
Skin thickness, n (%)	Thin: <1 cm	7 (22.6)	5 (16.7)	0.842 <sup>2</sup>
	Normal: 1-2 cm	18 (58.1)	19 (63.3)	
	Thick: >2 cm	6 (19.4)	6 (20)	

COS: Conventional osteotomy alone, COS-PRF: Conventional osteotomy plus platelet-rich fibrin, min.: Minute, SD: Standard deviation, min.-max.: Minimum-maximum  
<sup>1</sup>Mann-Whitney U test, <sup>2</sup> $\chi^2$  test, <sup>3</sup>Student's t-test



**Discussion**

Our findings revealed no significant difference between the COS and COS-PRF groups in terms of postoperative morbidity including eyelid edema, periorbital ecchymosis and pain after primary open rhinoplasty with conventional osteotomy. Overall, a higher-grade eyelid edema and periorbital ecchymosis as well as higher VAS and VRS pain scores and the analgesic use were evident on postoperative days 2 and 3, while all three parameters revealed improved scores with ease of postoperative morbidity on postoperative day 7 in both groups.

The higher edema and ecchymosis scores on postoperative day 2 vs. day 7 in the current study support the data from a past study revealed the higher postoperative edema and ecchymosis scores on day 2 vs. day 7 after conventional osteotomy (17-19). Also, given the previously reported VAS cut-off values of >3.1 (20,21) and >4.0 (22) to discriminate between mild and moderate pain, our findings indicate that our rhinoplasty patients, regardless of the use of PRF, had moderate pain only on postoperative day 2 (median VAS score: 4.0 for both groups). Likewise, in past studies using the same cut-off values, rhinoplasty patients were reported to have moderate pain only on the

**Table 2. Postoperative eyelid edema and periorbital ecchymosis in the COS vs. COS-PRF groups**

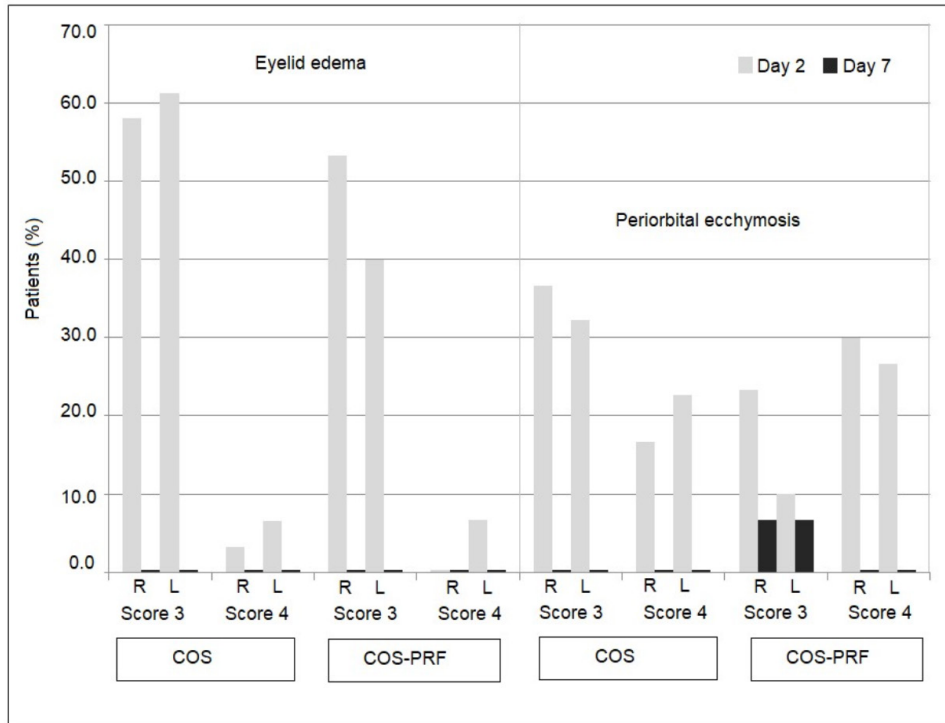
		COS (n=31)					COS-PRF (n=30)					p-value COS vs COS-PRF
Postoperative morbidity		0	1	2	3	4	0	1	2	3	4	
<b>Eyelid edema, n (%)</b>												
Day 2	Right	0	1 (3.2)	11 (35.5)	18 (58.1)	1 (3.2)	0	2 (6.7)	12 (40.0)	16 (53.3)	0	0.687
	Left	0	0	10 (32.3)	19 (61.3)	2 (6.5)	0	2 (6.7)	14 (46.7)	12 (40.0)	2 (6.7)	0.237
Day 7	Right	6 (19.4)	23 (74.2)	2 (6.5)	0	0	9 (30)	18 (60.0)	3 (10)	0	0	0.498
	Left	5 (16.1)	23 (74.2)	3 (9.7)	0	0	8 (26.7)	20 (66.7)	2 (6.7)	0	0	0.581
<b>Periorbital ecchymosis, n (%)</b>												
Day 2	Right	0	4 (13.3)	10 (33.3)	11 (36.7)	5 (16.7)	0	7 (23.3)	7 (23.3)	7 (23.3)	9 (30.0)	0.337
	Left	0	4 (12.9)	10 (32.3)	10 (32.3)	7 (22.6)	0	4 (13.3)	15 (50.0)	3 (10.0)	8 (26.7)	0.185
Day 7	Right	15 (48.4)	16 (51.6)	0	0	0	14 (46.7)	14 (46.7)	0	2 (6.7)	0	0.341
	Left	17 (54.8)	12 (38.7)	2 (6.5)	0	0	15 (50.0)	12 (40.0)	1 (3.3)	2 (6.7)	0	0.486

COS: Conventional osteotomy alone, COS-PRF: Conventional osteotomy plus platelet-rich fibrin  
 $\chi^2$  test and Fisher's exact test

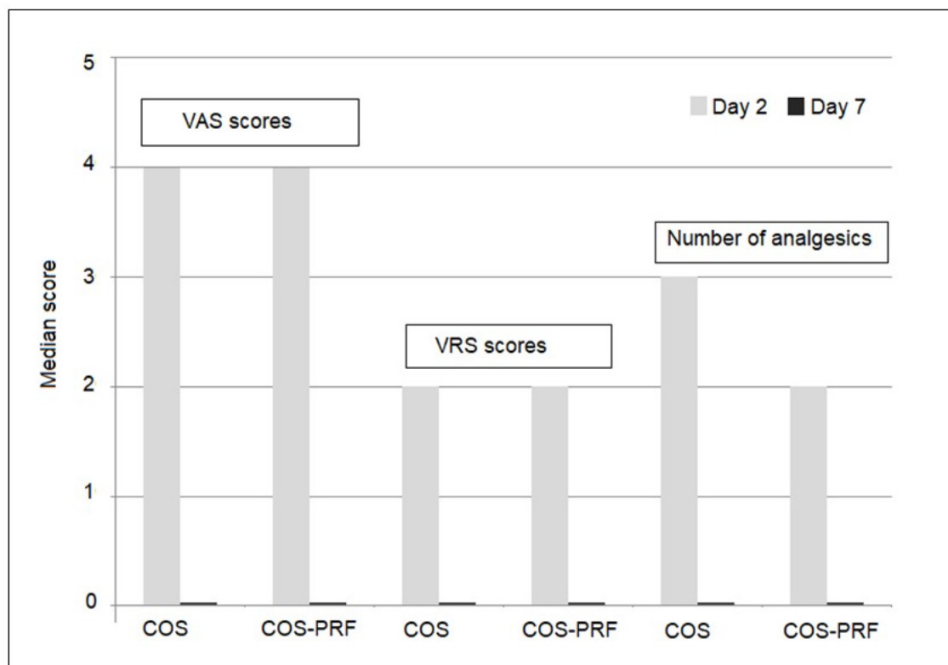
**Table 3. Postoperative pain and analgesic use in the COS versus COS-PRF groups**

	Postoperative scores									
	Day 1		Day 2		Day 3		Day 7		Average	
	Mean ± SD	Median (min.-max.)	Mean ± SD	Median (min.-max.)	Mean ± SD	Median (min.-max.)	Mean ± SD	Median (min.-max.)	Mean ± SD	Median (min.-max.)
<b>VAS scores</b>										
COS	3.3±2.2	3 (0-8)	3.9±2.3	4 (0-8)	3.3±2.2	3 (0-8)	0.9±1.2	0 (0-4)	2.9±1.7	2.5 (0-6.5)
COS-PRF	3.4±2.6	3 (0-9)	3.7±2.3	4 (0-9)	3±2.5	2 (0-9)	0.5±0.8	0 (0-2)	2.7±1.7	2.4 (0-6.8)
p-value	0.924 <sup>2</sup>		0.734 <sup>1</sup>		0.539 <sup>2</sup>		0.316 <sup>2</sup>		0.680 <sup>1</sup>	
<b>VRS scores</b>										
COS	1.5±1	1 (0-4)	2.1±1.2	2 (0-4)	1.7±1	2 (0-4)	0.5±0.7	0 (0-2)	1.4±0.7	1.5 (0-3.3)
COS-PRF	1.6±1.1	2 (0-4)	1.8±1.1	2 (0-4)	1.5±1.1	1 (0-4)	0.3±0.5	0 (0-1)	1.3±0.7	1.4 (0-3)
p-value	0.490 <sup>2</sup>		0.487 <sup>2</sup>		0.256 <sup>2</sup>		0.351 <sup>2</sup>		0.521 <sup>1</sup>	
<b>Number of analgesics</b>										
COS	1.1±1	1 (0-4)	2.8±1.1	3 (1-5)	2±1.2	2 (0-5)	0.4±0.8	0 (0-2)	1.6±0.8	1.5 (0.3-3.8)
COS-PRF	1.1±0.9	1 (0-4)	2.3±1.2	2 (0-5)	1.6±1.3	1 (0-5)	0.3±0.5	0 (0-2)	1.3±0.7	1.3 (0-3)
p-value	0.849 <sup>2</sup>		0.169 <sup>2</sup>		0.079 <sup>2</sup>		0.837 <sup>2</sup>		0.196 <sup>2</sup>	

COS: Conventional osteotomy alone, COS-PRF: Conventional osteotomy plus platelet-rich fibrin, VAS: Visual analogue scale, VRS: Verbal rating scale, SD: Standard deviation, min.-max.: Minimum-maximum  
<sup>1</sup>Student's t-test, <sup>2</sup>Mann-Whitney U test



**Figure 4.** Postoperative (day 2 and day 7) scores 3 and 4 postoperative eyelid edema and periorbital ecchymosis on the left and right side in conventional osteotomy (COS) and conventional osteotomy plus platelet-rich fibrin (COS-PRF) groups



**Figure 5.** Postoperative (day 2 and day 7) pain and analgesic use in conventional osteotomy (COS) and conventional osteotomy plus platelet-rich fibrin (COS-PRF) groups  
VAS: Visual analogue scale, VRS: Verbal rating scale

day of surgery (for a cut-off >4.0) or postoperative days 1 and 2 (for a cut-off >3.1) (23).

The association PRF with release of factors that improve and accelerate the tissue regeneration is considered to improve short-term postoperative outcome; whereas in the long term, PRF is considered to enable security and functional and aesthetic improvement after rhinoplasty (24-26). Hence, the practicality of PRF as well as its immuno-biologic properties is considered to make it an excellent alternative to other methods in rhinoplasty (1,12,27).

Notably, PRF is considered advantageous, particularly in structured rhinoplasty involving a small area of the body surface, given the likelihood of small and refined gains in the healing quality to offer lasting and satisfactory aesthetic and functional results (1).

Accordingly, PRF combined with autologous high-density fat-granule transplantation for augmentation rhinoplasty was reported to achieve a good and stable long-term effect with no adverse reactions and a good orthopedic and cosmetic effect (14).

In a past study on follow-up for 12 months a series of cases in which the PRF membrane was used as an alternative to the camouflage and filling-in techniques used in primary or secondary rhinoplasties, the authors reported that PRF membrane was an excellent surgical alternative to the camouflage and filling in rhinoplasty (1). The use of a cartilage graft wrapped in PRF matrix in open septorhinoplasty was also reported to be associated with successful results in dorsal grafting and tip area (28). Additionally, the application of PRF to the mucosal surface after the completion of septoplasty was reported to have a positive effect on olfactory function and pain, particularly in the early postoperative period (7).

Moreover, in a past study with 38 patients who underwent open approach primary rhinoplasty, the application of a PRF membrane over the bony dorsum and cartilage framework of the supratip area was reported to have a positive effect on postoperative edema, especially in the early postoperative period (13).

In contrast to the above-mentioned studies, our findings revealed no advantage of using local PRF application over osteotomy line in improving short-term postoperative morbidity among patients undergoing open rhinoplasty with conventional osteotomy. Nonetheless, given that 20% of our patients had thick nasal skin, note that in the long-term these patients may have benefit from the PRF application, since the use of PRF is suggested in patients with thicker skin and thus bigger tendency to form dead space to be filled with scar tissue, which consequently leads to persistent edema and poor cosmetic outcome (4,13).

Indeed, previous studies in the dentistry field also revealed no additional impact of using PRF or advanced PRF (A-PRF) on postoperative edema and pain after the mandibular third molar surgery (29-31), while A-PRF vs. PRF has also been reported to reduce postoperative pain, swelling and the analgesic need after the mandibular third molar surgery (32).

### Study Limitations

The major strength of the current study seems to be the assessment of postoperative morbidity via a graduated scoring system for eyelid edema and periorbital ecchymosis and via both VAS and VRS for pain. However, potential lack of generalizability seems to be an important limitation due to the relatively small sample size.

### Conclusion

Our findings on short-term postoperative morbidity among patients undergoing open rhinoplasty with conventional osteotomy indicate no significant impact of PRF application in reducing postoperative eyelid edema, periorbital ecchymosis, or pain within the first postoperative week. Larger scale studies addressing the efficacy of PRF along with other potential techniques, methods, or biomaterials for morbidity reduction may help reveal the optimal approach to reduce this uncomfortable postoperative morbidity in rhinoplasty patients and to enable long-term favorable outcomes regarding optimal healing and the intended morphologic result.

### Ethics

**Ethics Committee Approval:** Ethical approval for this study was obtained from the University of Health Sciences Turkey, Istanbul Training and Research Hospital Clinical Research Ethics Committee (approval no: 2011-KAEK-50/2687, date: 22.01.2021).

**Informed Consent:** Written informed consent was obtained from each patient.

**Peer-review:** Externally and internally peer-reviewed.

### Authorship Contributions

Concept: E.Y., T.K., O.O., O.Y., Design: E.Y., T.K., O.O., O.Y., Data Collection and/or Processing: E.Y., T.K., M.T., A.C., O.Y., Analysis and/or Interpretation: E.Y., T.K., M.T., A.C., Literature Research: E.Y., T.K., O.O., M.T., A.C., O.Y., Writing: E.Y., O.O., M.T., A.C., O.Y.

**Conflict of Interest:** No conflict of interest was declared by the authors.

**Financial Disclosure:** The authors declared that this study received no financial support.

### References

1. da S Neto MP, de S Almeida EC, da C C Tiveron LR, da Cunha MTR, Medeiros AG, Etchebehere RM. Use of the Autologous Membrane in Structured Rhinoplasty: An Alternative to Camouflaging and Filling. *Plast Reconstr Surg Glob Open* 2020;8:e3056.

2. Hatf DA, Ellsworth WA, Allen JN, Bullocks JM, Hollier LH Jr, Stal S. Perioperative steroids for minimizing edema and ecchymosis after rhinoplasty: a meta-analysis. *Aesthet Surg J* 2011;31:648-57.
3. Chan DS, Roskies M, Jooya AA, Samaha M. Postoperative Ecchymosis and Edema After Creation of Subperiosteal Tunnels in Rhinoplasty: A Randomized Clinical Trial. *JAMA Facial Plast Surg* 2019;21:133-6.
4. Dimić A, Stojilković V, Vujačić T. The use of piezoelectric instrumentation and platelet rich fibrin matrix in septorhinoplasty: Report of two cases. *Vojnosanitetski Pregled* July 2020;79.
5. Caglar E, Celebi S, Topak M, Develioglu NO, Yalcin E, Kulekci M. How can periorbital oedema and ecchymose be reduced in rhinoplasty? *Eur Arch Otorhinolaryngol* 2016;273:2549-54.
6. Karimi K, Rockwell H. The Benefits of Platelet-Rich Fibrin. *Facial Plast Surg Clin North Am* 2019;27:331-40.
7. Tutar B, Ekinoglu E, Karaketir S, et al. The impact of platelet-rich fibrin (PRF) on olfactory function and pain after septoplasty operations. *Eur Arch Otorhinolaryngol* 2020;277:1115-20.
8. Pires ALR, Bierhalz ACK, Moraes A. Biomaterials: types, applications, and market. *Quim Nova* 2015;38:957-71.
9. Dohan Ehrenfest DM, Rasmusson L, Albrektsson T. Classification of platelet concentrates: from pure platelet-rich plasma (P-PRP) to leucocyte- and platelet-rich fibrin (L-PRF). *Trends Biotechnol* 2009;27:158-67.
10. Farrior E, Ladner K. Platelet gels and hemostasis in facial plastic surgery. *Facial Plast Surg* 2011;27:308-14.
11. Xiong S, Qiu L, Su Y, Zheng H, Yi C. Platelet-Rich Plasma and Platelet-Rich Fibrin Enhance the Outcomes of Fat Grafting: A Comparative Study. *Plast Reconstr Surg* 2019;143:1201e-12.
12. Gode S, Ozturk A, Berber V, Kismali E. Effect of Injectable Platelet-Rich Fibrin on Diced Cartilage's Viability in Rhinoplasty. *Facial Plast Surg* 2019;35:393-6.
13. Gode S, Ozturk A, Kismali E, Berber V, Turhal G. The Effect of Platelet-Rich Fibrin on Nasal Skin Thickness in Rhinoplasty. *Facial Plast Surg* 2019;35:400-3.
14. Yan D, Li SH, Zhang AL, Xiao Y, Huang ZC. A Clinical Study of Platelet-Rich Fibrin Combined With Autologous High-Density Fat Transplantation in Augmentation Rhinoplasty. *Ear Nose Throat J* 2021;1455613211016902.
15. Kara CO, Gökalan I. Effects of single-dose steroid usage on edema, ecchymosis, and intraoperative bleeding in rhinoplasty. *Plast Reconstr Surg* 1999;104:2213-8.
16. Hawker GA, Mian S, Kendzerska T, French M. Measures of adult pain: Visual Analog Scale for Pain (VAS Pain), Numeric Rating Scale for Pain (NRS Pain), McGill Pain Questionnaire (MPQ), Short-Form McGill Pain Questionnaire (SF-MPQ), Chronic Pain Grade Scale (CPGS), Short Form-36 Bodily Pain Scale (SF-36 BPS), and Measure of Intermittent and Constant Osteoarthritis Pain (ICOAP). *Arthritis Care Res (Hoboken)* 2011;63 (Suppl 11):S240-52.
17. Taşkın Ü, Batmaz T, Erdil M, Aydın S, Yücebaş K. The comparison of edema and ecchymosis after piezoelectric and conventional osteotomy in rhinoplasty. *Eur Arch Otorhinolaryngol* 2017;274:861-5.
18. Yildirim YSS, Seneldir S, Cetiner H. The Comparison of Conventional Osteotomes and Magic Saws in Terms of Edema and Ecchymosis After Rhinoplasty. *J Craniofac Surg* 2022;33:e4-8.
19. McGuire C, Boudreau C, Prabhu N, Hong P, Bezuhly M. Piezosurgery versus Conventional Cutting Techniques in Craniofacial Surgery: A Systematic Review and Meta-Analysis. *Plast Reconstr Surg* 2022;149:183-95.
20. Bodian CA, Freedman G, Hossain S, Eisenkraft JB, Beilin Y. The visual analog scale for pain: clinical significance in postoperative patients. *Anesthesiology* 2001;95:1356-61.
21. Myles PS, Myles DB, Galagher W, et al. Measuring acute postoperative pain using the visual analog scale: the minimal clinically important difference and patient acceptable symptom state. *Br J Anaesth* 2017;118:424-9.
22. Jensen MP, Chen C, Brugger AM. Interpretation of visual analog scale ratings and change scores: a reanalysis of two clinical trials of postoperative pain. *J Pain* 2003;4:407-14.
23. Sclafani AP, Kim M, Kjaer K, Kacker A, Tabae A. Postoperative pain and analgesic requirements after septoplasty and rhinoplasty. *Laryngoscope* 2019;129:2020-5.
24. Dohan DM, Choukroun J, Diss A, et al. Platelet-rich fibrin (PRF): a second-generation platelet concentrate. Part I: technical origin concepts and evolution. *Oral Surg Oral Med Oral Pathol Oral Radiol Endod* 2006;101:e37-44.
25. Dohan Ehrenfest DM, Pinto NR, Pereda A, et al. The impact of the centrifuge characteristics and centrifugation protocols on the cells, growth factors, and fibrin architecture of a leukocyte- and platelet-rich fibrin (L-PRF) clot and membrane. *Platelets* 2018;29:171-84.
26. Dong W, Han R, Fan F. Diced Cartilage Techniques in Rhinoplasty. *Aesthetic Plast Surg* 2021.
27. Santos M, Ribeiro A, Almeida E Sousa C, et al. Shaved Cartilage Gel Versus Diced Cartilage on Final Dorsal Camouflage: Prospective Study of 200 Patients. *Facial Plast Surg Aesthet Med* 2021;23:164-71.
28. Guler I, Kum RO, Yilmaz YF. Application Of Platelet Rich Fibrin Matrix (PRFM) In Septorhinoplasty. *ENT Updates* 2019;9:53-8.
29. Torul D, Omezli MM, Kahveci K. Evaluation of the effects of concentrated growth factors or advanced platelet rich-fibrin on postoperative pain, edema, and trismus following lower third molar removal: A randomized controlled clinical trial. *J Stomatol Oral Maxillofac Surg* 2020;121:646-51.
30. Gülşen U, Şentürk MF. Effect of platelet rich fibrin on edema and pain following third molar surgery: a split mouth control study. *BMC Oral Health* 2017;17:79.
31. Bao MZ, Liu W, Yu SR, Men Y, Han B, Li CJ. Application of platelet-rich fibrin on mandibular third molar extraction: systematic review and Meta-analysis. *Hua Xi Kou Qiang Yi Xue Za Zhi* 2021;39:605-11.
32. Caymaz MG, Uyanik LO. Comparison of the effect of advanced platelet-rich fibrin and leukocyte- and platelet-rich fibrin on outcomes after removal of impacted mandibular third molar: A randomized split-mouth study. *Niger J Clin Pract* 2019;22:546-52.