

An Unusual Cause of Syncope in a Patient with Prosthetic Aortic Valve

Protez Aort Kapaklı Bir Hastada Olağandışı Senkop Etiyolojisi

Alper Aydın, Tayfun Gürol, Mustafa Serdar Yılmaz, Bahadır Dağdeviren

Maltepe University School of Medicine, Department of Cardiology, Istanbul, Turkey

Abstract

The authors present the case of a patient with aortic valve surgery and unexplained syncopal attacks. With the use of an implantable loop recorder, sinus node dysfunction was diagnosed more than 4 months after implantation. This case highlights the importance of implantable loop recorders in patients with unexplained syncope and that atrioventricular block is not the only mechanism of syncope in patients with aortic valve surgery. (*The Medical Bulletin of Haseki 2012;50: 37-8*)

Key Words: Syncope, prosthetic valve, implantable loop recorder, sinus pause

Özet

Aort kapak operasyonu öyküsü bulunan hastalarda senkop etiyolojisi daha çok atriyoventriküler düğümdeki ileti defektlerine bağlıdır. Aort darlığı nedeni ile protez kapak implantasyonu yapılan ve sonrasında senkop atakları olan hastanın tanısı implante edildikten 4 ay sonra takılabilir loop kaydedici yardımı ile sinüs düğümü disfonksiyonu olarak belirlenebilmiştir. Bu vaka aort kapak operasyon öyküsü bulunan bir hastada olağandışı senkop etiyolojisini ve konvansiyonel testlerin yetersiz kaldığı durumlarda uzun dönemli kayıt imkânı sunan loop kaydedicilerin tanısız önemini göstermektedir. (*Haseki Tıp Bülteni 2012; 50: 37-8*)

Anahtar Kelimeler: Senkop, protez kapak, takılabilir loop kaydedici, sinus duraklaması

Introduction

In patients with aortic valve surgery, syncopal episodes are usually due to complete atrioventricular (AV) block. Damage to the conduction system in this group of patients is commonly due to surgical trauma, hematoma, extending calcification and ischemia. This case reveals an unusual mechanism of syncope in a patient with aortic valve replacement. The diagnosis was undertaken using an implantable loop recorder (ILR).

Case Report

A 55-year-old male patient experienced 3 syncope episodes within a year. All episodes occurred at daytime. One episode occurred while he was sitting and the two others, in upright position. He had no prodromal symptoms. In all of the episodes, he became conscious immediately after syncopal attack. There were no neurological symptoms or loss of sphincter control. In the

last episode, he had a nose fracture. Except for the fracture, he was asymptomatic.

Upon admission, he was conscious and was able to give his full history. He had aortic valve replacement (AVR) with a bileaflet metallic prosthetic valve 3 years ago and he has been on oral anticoagulant medication. His physical and neurological examination was normal except for the nasal fracture and prosthetic valve sounds. A 12-lead ECG revealed normal sinus rhythm with a rate of 76 bpm.

Transthoracic and transesophageal echocardiography revealed normal prosthetic aortic valve function. Carotid sinus massage, 24-hour Holter monitoring and tilt-table test showed no abnormalities. Electrophysiological examination showed normal sinus and AV nodal functions. (AH interval: 78 msn, HV interval: 47 msn, basal cycle length: 760 msn, corrected sinus node recovery time: 515 msn, AV node Wenckebach interval: 300 msn) With ventricular stimulation, no ventricular tachycardia (VT) was induced. A neurologic workup with cranial and carotid imaging was also normal. To

Address for Correspondence/Yazışma Adresi: Alper Aydın
Maltepe University School of Medicine, Department of Cardiology, Istanbul, Turkey
GSM: +90 542 585 55 19 E-mail: dralperaydin@gmail.com

Received/Geliş Tarihi: 30 December 2010 **Accepted/Kabul Tarihi:** 07 March 2011

The Medical Bulletin of Haseki Training and Research Hospital, published by Galenos Publishing. All rights reserved.

Haseki Tıp Bülteni,
Galenos Yayınevi tarafından basılmıştır. Her hakkı saklıdır.

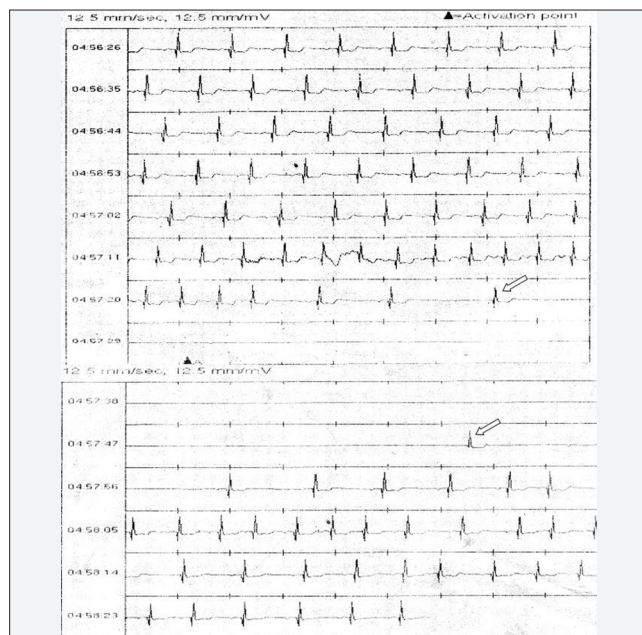


Figure 1. ILR recording demonstrating sinus pause of 31 seconds interrupted by a junctional beat after 20 seconds. Arrows represent junctional escape beats

determine the cause of the syncopal attacks, an ILR (Reveal Plus Medtronic Inc. Minneapolis) was implanted subsequently.

Four months after implantation, the patient would awaken from sleep with a feeling of nausea, lightheadedness and sweating. The ILR revealed a sinus pause of 31 seconds interrupted by a junctional beat after 20 seconds. (Figure 1) A dual chamber pacemaker with lower rate 60 bpm and a long fixed AV delay (275 msec) was implanted. The patient had no syncopal episodes during one-year follow-up. Assessment of the pacemaker data showed predominantly intrinsic rhythm (88%) with atrial pacing at 10% and atrial sensing and ventricular pacing at 2%.

Discussion

Complete AV block is a known complication of aortic valve surgery and may also be seen in various aortic root diseases (1-5). Surgical trauma to the conduction system during AVR has been described in autopsy reports on subjects who died after surgery (6). Apart from surgical trauma; ischemia, dissecting hematomas, and extending calcification or granulomas may affect the conduction system. New conduction defects were also found in 33% of patients after AVR, with left branch bundle block (BBB) being the most commonly encountered anomaly (7). A new and persistent BBB acquired after AVR is associated with an increased adverse event rate (8).

Recurrent episodes of unexplained syncope may be due to many factors. Electrophysiology studies can be useful for evaluating sinus node function, AV nodal and His-Purkinje

system conduction. The diagnostic yield of electrophysiology studies in patients with a structurally normal heart and a normal ECG is low (1% ventricular tachycardia, 10% bradycardia) whereas in patients with organic heart disease, the yield is over 50% (21% ventricular tachycardia, 34% bradycardia) (9). Patients with an abnormal ECG also have a significant diagnostic yield (17% ventricular tachycardia, 19% bradycardia). A negative electrophysiology study does not necessarily exclude an arrhythmic cause of syncope and has a poor predictive value in nonischemic cardiomyopathy, long QT syndrome, mitral valve prolapse, and the Brugada syndrome (10). The use of implantable loop recorders leads to successful documentation of bradyarrhythmias in patients with previously unexplained syncope (11).

In our case, prolonged sinus arrest was the cause of the syncopal attacks. When bradycardic episode occurs before an episode of asystole, the cause of the asystole is attributed to an increased vagal tone. But the sudden onset of patients' attacks and negative tilt-table test makes the diagnosis of neurally mediated syncope, unlikely.

This case study demonstrates that in patients with aortic valve replacement, AV block is not the only cause of syncope. ILRs are useful diagnostic tools for patients who exhibit infrequent symptoms and have normal results of conventional diagnostic tests.

References

1. Plack RH, Porterfield JK, Brinker JA. Complete heart block developing during aortic valvuloplasty. *Chest* 1989;6:1201-3.
2. Sukenik S, Pras A, Buskila D, Katz A, Snir Y, Horowitz J. Cardiovascular manifestations of ankylosing spondylitis. *Clin Rheumatol* 1987;6:588-92.
3. Russo G, Tamburino C, Bianca I, et al. Conduction disorders in aortic periprosthetic abscesses. *Cardiologia* 1989;34:629-33.
4. Von Oppell UO, Chimuka D, Brink JG, Zilla P. Aortic dissection repair with GRF glue complicated by heart block. *Ann Thorac Surg* 1995;59:761-3.
5. Lorenzoni R, Santoro GM, Calamai G, Masini G. Total atrioventricular block as the primary clinical manifestation of undiagnosed aortic dissection. *G Ital Cardiol* 1995;25:1031-5.
6. Fuduka T, Hawley RL, Edwards JE. Lesions of conduction tissue complicating aortic valvular replacement. *Chest* 1976;69:605-14.
7. Fournial JF, Brodaty D, Chomette G, Tereau Y, Cabrol C, Acar J. Conduction disorders after aortic valve replacement. A propos of 200 cases. *Arch Mal Coeur Vaiss* 1979;72:4-11.
8. Khally Z, Thibault B, Staniloae C, Theroux P, Dubuc M, Roy D, et al. Prognostic significance of newly acquired bundle branch block after aortic valve replacement. *Am J Cardiol* 2004; 94:1008-11.
9. Linzer M, Yang EH, Estes NA 3rd, Wang P, Vorperian VR, Kapoor WN. Diagnosing syncope. Part 2: Unexplained syncope. Clinical Efficacy Assessment Project of the American College of Physicians. *Ann Intern Med* 1997;127:76-86.
10. DiMarco JP. Value and limitations of electro-physiology testing for syncope. *Cardiol Clin* 1997;15:219-32.
11. Krahn AD, Klein GJ, AL, Skanes AC, Yee R. Insertable Loop Recorder Use for Detection of Intermittent Arrhythmias. *Pacing Clin Electrophysiol* 2004;27:657-64.