



Anesthesia Management in Tracheobronchial Anomaly Case Detected During Tracheotomy: A Case Report

✉ Gamze Kucukosman*, ✉ Zeynep Gurbuz*, ✉ Sule Altuncu*, ✉ Rahsan Dilek Okay*,
✉ Duygu Erdem**

*Zonguldak Bulent Ecevit University Faculty of Medicine, Department of Anesthesiology and Reanimation, Zonguldak, Turkey

**Zonguldak Bulent Ecevit University Faculty of Medicine, Department of Otorhinolaryngology, Zonguldak, Turkey

Abstract

Tracheobronchial anomalies (TBA) are abnormal airway pathologies that originate from the primary branching site of the tracheobronchial tree, and their prevalence is 0.1-0.2%. The tracheal bronchus and accessory cardiac bronchus are among the most common TBAs. Although these anomalies are usually asymptomatic, they manifest as respiratory tract infections, hemoptysis, atelectasis, and respiratory distress. Appropriate identification and detection of these anomalies are vital in anesthesia management. Accidental cannulation of a tracheal bronchus with an anomaly can prevent ventilation of all other bronchopulmonary segments, and due to potential hyperinflation, pneumothorax secondary to alveolar rupture may develop. In this case presentation, we shared our anesthesia method applied to a child with a tracheobronchial anomaly that was coincidentally detected during a tracheotomy.

Keywords: Tracheotomy, tracheobronchial anomaly, anesthesia management, rare case

Introduction

Tracheobronchial anomalies (TBA) are abnormal airway pathologies that originate from the primary branching site of the tracheobronchial tree, and their prevalence is 0.1-0.2% (1-3). They are more frequently seen in children with anomalies such as Down syndrome, congenital cardiomyopathy, or lung malformations (4). Although these anomalies are usually asymptomatic, they manifest as respiratory tract infections, hemoptysis, atelectasis, and respiratory distress (5,6). Most patients are treated without surgery, but if they have permanent or recurring upper lobe pneumonia or atelectasis, the relevant segment must be removed surgically (2). Appropriate identification and detection of these anomalies are vital in anesthesia management (7-9). If you accidentally cannulate a tracheal bronchus that has a problem, it can stop all the other bronchopulmonary segments from breathing. This can lead to hyperinflation, which can cause an alveolar rupture and a pneumothorax. An intubation tube can plug the lumen of the tracheal bronchus and lead to postoperative

hypoxemia and weaning difficulties (2-4,7-9). In this case presentation, we shared our anesthesia method applied to a child with a tracheobronchial anomaly that was coincidentally detected during a tracheotomy.

Case Report

Family consent was obtained for the case presentation. The patient with intrauterine growth retardation was born spontaneously vaginally without complications due to oligohydramnios weighing 3.010 g at 39 weeks of gestation.

The patient, who did not stay in the incubator and was noticed not being able to hold her head in routine controls made when she was 2-3 months old, was evaluated by pediatric neurology, and although its etiology was not fully clarified, it was learned that she could have cerebral palsy (CP) secondary to asphyxia. The patient started to turn purple while crying and had seizures afterwards, developing aspiration pneumonia. She was hospitalized in the intensive care unit (ICU) for follow-up and treatment. In her

Presented in: Travma Anestezisinde Hasta Güvenliği, Zonguldak'ta Sonbahar Sempozyumu-III, 12 November 2022, Zonguldak, Turkey

Address for Correspondence: Gamze Kucukosman, Zonguldak Bulent Ecevit University Faculty of Medicine, Department of Anesthesiology and Reanimation, Zonguldak, Turkey

Phone: +90 532 566 25 71 **E-mail:** gamzebeu@gmail.com **ORCID:** orcid.org/0000-0002-3586-7494

Received: 10.10.2023 **Accepted:** 05.02.2024



follow-up in the ICU, an increase was observed in her already existing stridor, and a tracheotomy was planned because of CP-related muscle hypotonia and laryngomalacia. In the pre-operative physical examination of the patient, who was 9 months old and weighed 6 kg with no specific family history, retrognathia, distinct premaxilla, long philtrum, hypertonic extremities, and deep palmar lines were observed. The preoperative values of the patient were normal.

The patient was breathing spontaneously, and standard anesthesia monitoring was applied. Her blood pressure was 120/80 mmHg, her pulse was 120/min, and her SpO₂ in the room ambience was 98%. After preoxygenation, anesthesia induction (20 mg propofol, 5 mg lidocaine, 10 mcg fentanyl, and 3 mg rocuronium) was performed, and intubation with Macintosh blade no. II was planned. The laryngoscope was quickly replaced with a C-MAC® videolaryngoscope in a patient with Cormack-Lehane grade 3. The patient was intubated with a number 3.5 endotracheal tube (ETT) on the first attempt without complications. By confirming the tube site through bilateral lung sounds and end-tidal carbon monoxide pressures, the tube was fixed. Anesthesia maintenance was provided with 2.5-3% sevoflurane, a 50%: O₂:air mixture, and a remifentanyl infusion.

After an incision was made between the 2nd-3rd tracheal cartilages and tracheotomy cannula number 4 was placed smoothly, the patient could not be ventilated. The patient was intubated again with the same ETT. The hemodynamic parameters of the patient followed a stable course throughout anesthesia, and a small tracheotomy cannula numbered 0.5 was placed. However, the patient was re-intubated because ventilation could not be provided. An intraoperative flexible endoscopy was performed on the patient, who was stable in terms of ventilation after intubation but could not be ventilated through the tracheotomy cannula. Endoscopy revealed a third

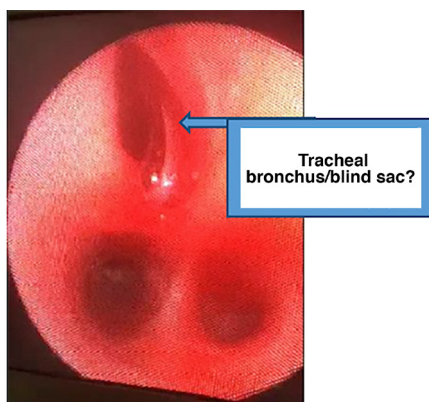


Figure 1. A third pathway (tracheal bronchus?/blind sac?) on the carina

pathway (tracheal bronchus/blind sac?) above the carina line (Figure 1). Because of intraoperative consultations with pediatric and chest surgery clinics, it was thought that the canula may have entered this pathway due to the tracheal anomaly in the case and therefore could not be ventilated. The stoma of the patient was closed, and she was transferred to the pediatric ICU as an intubated patient to be evaluated by an advanced center.

Discussion

The respiratory system starts to develop in the third week of gestation, and the development of the tracheobronchial tree from its main branches to the terminal bronchioles is completed in the 16th week of intrauterine life. Tracheobronchial anomalies occur during this period. The tracheal bronchus and accessory cardiac bronchus are among the most common TBAs. Tracheal bronchi are anomalies that originate from the trachea and main bronchi (1,10). The prevalence of tracheal bronchus is 0.1-2% on the right and 0.3-1% on the left (1). A few anatomical types of tracheal bronchus have been described: if the upper lobe bronchus does not have a branch and there is an aberrant bronchus in the middle, it is called "displaced bronchus"; if it is concurrent with a normal upper lobe bronchus, it is called "supernumerary bronchus" (1).

The majority of TBAs in adults are asymptomatic, and only by chance are they detected through bronchoscopy or radiological imaging (2). On the other hand, in pediatric patients, they are associated with airway diseases such as recurring pneumonia and hemoptysis. Therefore, they are detected in children earlier and more frequently than in adults (4). Anomalies in the tracheobronchi can lead to respiratory problems like atelectasis, hemoptysis, recurrent or permanent lower respiratory tract infections, focal emphysema (especially in the upper lobe), bronchiectasis, and cystic malformation (5,6), even though they don't usually cause any symptoms. Stridor at birth should suggest congenital anomalies, whereas stridor that starts in the 4-6th week should indicate laryngomalacia and tracheomalacia (5). Bronchoscopy is recommended for all patients who present with recurrent lung infection and stridor without a known cause (2,11). Bronchoscopy is useful preoperatively because it will provide a clear image of TBAs. However, because the origin of TB may be similar to the tracheal bifurcation in the carina, the diagnosis of TB may be overlooked. Computed tomography (CT) is useful for understanding the structure of TBAs and their relationship with surrounding tissues. Magnetic resonance imaging has some disadvantages, such as a longer imaging time than CT, creating motion-related artifacts, and requiring long-term sedation (1-4,12). Congenital anomalies and the association of early-onset stridor with

laryngomalacia should have been considered. In our case, for which the cause of the stridor was not investigated before surgery, an intraoperative flexible endoscopy was performed because of the problems, and a right TB was detected 2-3 cm above the carina. Because the right upper lobe was not examined in detail during the intraoperative period, we believe that the tracheotomy cannula was placed in this stump, disrupting ventilation, and that it may be a supernumerary bronchus.

Tracheobronchial anomalies can lead to severe complications in airway management (7-9). An endotracheal tube cuff can plug TB and prevent ventilation of the right upper lobe. A TB can be accidentally cannulated, in which case the remaining lobes of the right and left lungs cannot be ventilated. In both cases, perioperative hypoxemia and atelectasis can develop. Therefore, TB, albeit rarely, should be considered in the differential diagnosis of desaturation cases related to endotracheal intubation (2-6). To prevent complications, it is recommended to use a short ETT (to prevent TB obstruction) or to fix the tube by performing the intubation procedure using fiberoptic bronchoscopy (7). Conacher (13) suggested that in cases where desaturation develops due to the obstruction of TB with ETT, ETT should be carefully withdrawn by performing right upper lobe auscultation and waiting for the improvement in SpO₂. In our case, in which ventilation was provided after intubation but ventilation could not be ensured despite the placement of a smaller tracheotomy canula for the second time, it was thought that the intubation tube and cuff provided ventilation by staying over the region with TBA and that the tracheotomy canula disrupted ventilation by entering TB. In our case, who was brought to the operating room with spontaneous respiration, to ensure the safety of the procedure to be applied in case of respiration distress that may develop postoperatively and to eliminate the possibility of an accidental TB cannulation, the stoma of the patient was closed and transferred to the intensive care unit as intubated.

Conclusion

It should be kept in mind that various bronchial anomalies can develop in pediatric patients who have congenital anomalies and stridor. In these situations, a thorough preoperative evaluation should include fiberoptic bronchoscopy and a radiological examination like computed tomography for safe anesthesia management. This will show any TBAs and help with planning airway management strategies and reducing complications.

Ethics

Informed Consent: Written informed consent was obtained from the patient's parent for publication of the case report and the accompanying images.

Authorship Contributions

Concept: G.K., Z.G., S.A., Design: G.K., Z.G., Data Collection or Processing: Z.G., S.A., D.E., Literature Search: G.K., Z.G., R.D.O., Writing: G.K., Z.G., R.D.O., Critical Review: R.D.O., S.A.

Conflict of Interest: The authors declare no conflicts of interest with respect to the authorship and/or publication of this article.

Financial Disclosure: The authors received no financial support for the research and/or authorship of this article.

References

1. Ghaye B, Szapiro D, Fanchamps JM, Dondelinger RF. Congenital bronchial abnormalities revisited. *Radiographics* 2001;21:105-19.
2. Findik S. Tracheal bronchus in the adult population. *J Bronchology Interv Pulmonol* 2011;18:149-53.
3. Dave MH, Gerber A, Bailey M, et al. The prevalence of tracheal bronchus in pediatric patients undergoing rigid bronchoscopy. *J Bronchology Interv Pulmonol* 2014;21:26-31.
4. Wong LM, Cheruiyot I, de Oliveira MHS, et al. Congenital anomalies of the tracheobronchial tree: a meta-analysis and clinical considerations. *Ann Thorac Surg* 2021;112:315-25.
5. Uçar Ş, Adaklı B, Çelik B, et al. Evaluation of etiology in infants with recurrent pneumonia and chronic stridor. *Turk Toraks Derg* 2014;15:122-7.
6. Bozkuş F, Atilla N, Arpağ H, Kahraman H. A rare case of tracheobronchial anomaly: tracheal Bronchus. *KSU Tıp Fak Der* 2015;10:27-8.
7. McAllister RK, Sirianni C, Beckendorf R. Implications of endotracheal tube placement in a patient with a true tracheal bronchus. *Proc (Bayl Univ Med Cent)* 2019;32:138-9.
8. Lee DK, Kim YM, Kim HZ, Lim SH. Right upper lobe tracheal bronchus: anesthetic challenge in one-lung ventilated patients -A report of three cases-. *Korean J Anesthesiol* 2013;64:448-50.
9. Wiser SH, Hartigan PM. Challenging lung isolation secondary to aberrant tracheobronchial anatomy. *Anesth Analg* 2011;112:688-92.
10. Sánchez I, Navarro H, Méndez M, Holmgren N, Caussade S. Clinical characteristics of children with tracheobronchial anomalies. *Pediatr Pulmonol* 2003;35:288-91.
11. Boudewyns A, Claes J, Van de Heyning P. Clinical practice: an approach to stridor in infants and children. *Eur J Pediatr* 2010;169:135-41.
12. Suzuki M, Matsui O, Kawashima H, et al. Radioanatomical study of a true tracheal bronchus using multidetector computed tomography. *Jpn J Radiol* 2010;28:188-92.
13. Conacher ID. Implications of a tracheal bronchus for adult anaesthetic practice. *Br J Anaesth* 2000;85:317-20.