



A Rare Congenital Cardiac Anomaly Presenting with Amaurosis Fugax: Quadricuspid Aortic Valve

Amarozis Fugaks ile Prezente Olan Nadir Görülen Doğuştan Kalp Anomalisi: Kuadriküspid Aort Kapak

İbrahim Altun, Fatih Akın, Nuri Köse

Muğla Sıtkı Koçman University Faculty of Medicine, Department of Cardiology, Muğla, Turkey

Abstract

Quadricuspid aortic valve (QAV) is a rare cause of aortic regurgitation. Most cases are detected incidentally during echocardiography, angiography, autopsy or surgery. It may also be associated with other congenital anomalies of the heart. A 27-year-old male was admitted to our department to evaluate the etiology of amaurosis fugax. On physical examination, his blood pressure was 125/85 mmHg, and an evident diastolic murmur of grade 2/6 was heard at the third left intercostal space. Results of electrocardiography and chest radiography were normal. Transthoracic and transoesophageal echocardiography revealed a quadricuspid aortic valve, a mild aortic regurgitation. The importance of recognizing this condition lies in the fact that more than 50% of people with QAV require valve replacement in the fifth or sixth decade of life, because of worsening aortic regurgitation. (*The Medical Bulletin of Haseki 2014; 52: 302-3*)

Key Words: Amaurosis fugax, aortic regurgitation, quadricuspid aortic valve, echocardiography

Özet

Kuadriküspid aort kapak, aort yetersizliğinin nadir bir nedenidir. Vakaların çoğu ekokardiyografi, otopsi veya cerrahi sırasında rastlantısal olarak saptanır. Bu anomali diğer doğuştan kalp anomalileri ile birlikte olabilmektedir. Yirmi yedi yaşındaki hasta amarozis fugaks etyolojisinin değerlendirilmesi amacıyla servisimize yatırıldı. Fizik muayenesinde kan basıncı 125/85 mmHg olup sol 3. interkostal aralıkta 2/6 diyastolik üfürüm mevcuttu. Bakılan elektrokardiyografi ve akciğer grafisi normal saptandı. Hastaya yapılan transtorasik ve transözofajiyal ekokardiyografide kuadriküspid aort kapak ve hafif aort yetersizliği saptandı. Kuadriküspid aort kapağı olan hastaların %50'sinden fazlasında beşinci veya altıncı dekatta aort yetersizliğinin kötüleşmesine bağlı aort kapak replasmanı gerektirdiğinden tanınması önemlidir. (*Haseki Tıp Bülteni 2014; 52: 302-3*)

Anahtar Sözcükler: Amarozis fugaks, aort yetersizliği, kuadriküspid aort kapak, ekokardiyografi

Introduction

Quadricuspid aortic valve (QAV) is a rare congenital malformation, far less common than bicuspid or unicuspid aortic valves (1). Most of the cases are discovered incidentally at necropsy, during aortic valve replacement, or aortic angiography (2). The first case of QAV was reported in 1862 (3). Around 200, mainly adult cases have been described in the literature. Aortic regurgitation is the most frequent valvular dysfunction in patients with a QAV, whereas valvular stenosis is very rare (4). Echocardiographic examination plays an important role in the diagnosis. We report a case of QAV presenting with amaurosis fugax.

Case Report

A 27-year-old male was admitted to our department for the evaluation of the etiology of amaurosis fugax. Physical examination revealed a blood pressure of 125/85 mmHg, respiratory rate of 23/min and a pulse rate of 84/min. On cardiac auscultation, heart sounds were soft 2/6 diastolic murmur was heard at the left sternal border. The respiratory sounds on auscultation were normal. The electrocardiogram and chest X-ray were normal. The transthoracic echocardiogram showed mild aortic regurgitation without the usual Y-aspect trileaflet closure. The aortic valve appeared abnormal and possibly

Address for Correspondence/Yazışma Adresi: İbrahim Altun
Muğla Sıtkı Koçman University Faculty of Medicine, Department of Cardiology, Muğla, Turkey
Phone: +90 252 211 51 74 E-mail: ibrahim_altun@yahoo.com

Received/Geliş Tarihi: 26 April 2014 **Accepted/Kabul Tarihi:** 10 May 2014

*The Medical Bulletin of Haseki Training and Research Hospital,
published by Galenos Publishing.*

Haseki Tıp Bülteni,
Galenos Yayınevi tarafından basılmıştır.

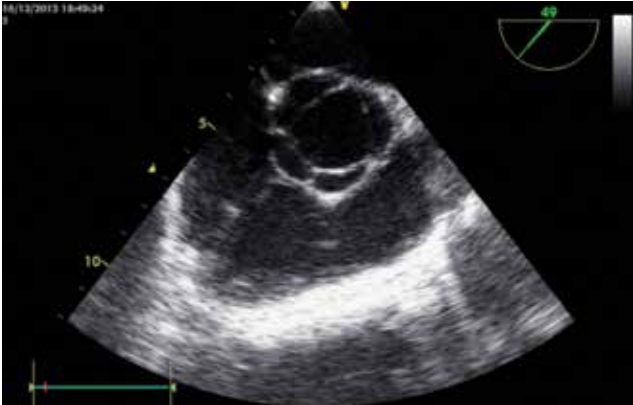


Figure 1. Transesophageal echocardiography revealed quadricuspid aortic valve

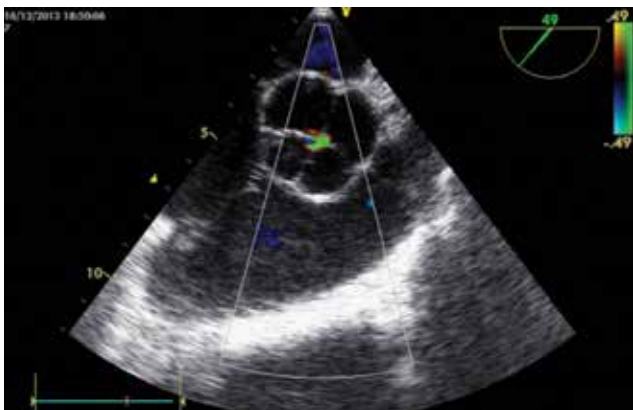


Figure 2. Transesophageal echocardiography revealed mild aortic regurgitation

quadricuspid. Transesophageal echocardiography (TEE) was performed for a detailed examination of the aortic valve. TEE revealed QAV with an X-shaped commissural aspect in diastole and mild aortic regurgitation (Figure 1, 2).

Discussion

A normal aortic valve is composed of three symmetric cusps. Abnormal cusps may be formed as a result of a developmental anomaly during embryological arterial trunk septation. QAV is a very rare form of congenital valvular malformation with a reported incidence ranging

from 0.008% to 0.033% (1). Most cases are detected incidentally on echocardiography, during angiography. Previously, when echocardiography was not available, most of the diagnosis of QAV was established during aortic valve surgery or autopsy. Up to 18% of patients will have other cardiac malformations, the most common being a coronary artery anomaly (2). Atrial septal defect, pulmonary valve stenosis, hypertrophic cardiomyopathy, ventricular septal defect, and subaortic stenosis have also been described (3,4). The median age at diagnosis is 49 years and the diagnosis is more frequent in male patients (5). According to anatomy of the four cusps, Hurwitz and Roberts categorized QAV into seven subtypes (A to G) (6). The two most frequent types are type A (four equal cusps) and type B (three normal cusps with one smaller cusp). Our case belonged to type A. Aortic regurgitation is the predominant valvular dysfunction associated with QAV, whereas valvular stenosis is very rare.

Quadricuspid aortic valve is a very uncommon congenital malformation, occurring separately or associated with other congenital disorders. It is responsible for regurgitation more often than stenosis. TEE is helpful for the diagnosis and precise description of the mechanism of the regurgitation.

References

1. Hurwitz LE, Roberts WC. Quadricuspid semilunar valve. *Am J Cardiol* 1973;31:623-6.
2. Janssens U, Klues HG, Hanrath P. Congenital quadricuspid aortic valve anomaly associated with hypertrophic non-obstructive cardiomyopathy: a case report and review of the literature. *Heart* 1997;78:83-7.
3. Robicsek F, Sanger PW, Daugherty HK, Montgomery CC. Congenital quadricuspid aortic valve with displacement of the left coronary orifice. *Am J Cardiol* 1969;23:288-90.
4. Tutarel O. The quadricuspid aortic valve: A comprehensive review. *J heart Valve Disease* 2004;13:534-7.
5. Formica F, Sangalli F, Ferro O, Paolini G. A rare cause of severe aortic regurgitation: Quadricuspid aortic valve. *Interact Cardiovasc Thorac Surg* 2004;3:672-4.
6. Feldman BJ, Khandheria BK, Warnes CA, Seward JB, Taylor CL, Tajik AJ. Incidence, description and functional assessment of isolated quadricuspid aortic valves. *Am J Cardiol* 1990;65:937-8.